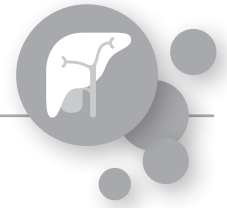

# Case Report.



## INTRAHEPATIC CHOLANGIOCARCINOMA (ICC) TREATED WITH DSM-TACE

Author: **Enzo Gabriele Maria Antonuccio, MD.**  
Interventional Radiology Consultant  
San Giovanni – Addolorata Hospital, Rome, Italy



### Patient

- 84 year old female
- Stage III N0 M0 intrahepatic cholangiocarcinoma (ICC) involving segments IV-V-VI-VII diagnosed in August 2019
- Starting oral Capecitabine therapy in September 2019
- Lab Parameters: **HB** 11.5 g/dl | **PLT** 164.000  $\mu$ l | **ALT** 31 U/l | **AST** 53 U/l, **Serum bilirubin** 1.2 mg/dl | **Creatinine** 0.8 mg/dl | **INR** 1.14
- Abdominal follow-up CT-scan showed disease progression in December 2019 | Fig 1a-c
- Tumor board decision:
  - **DSM-TACE** with 50 mg Doxorubicin
  - **Monolobar treatment** planned (two treatments at 2-month interval; first treatment was targeted to posterior segmental branch of right hepatic artery, feeding segments VI-VII (lobes more involved by disease), second treatment targeted to anterior segmental branch feeding segments IV-V)

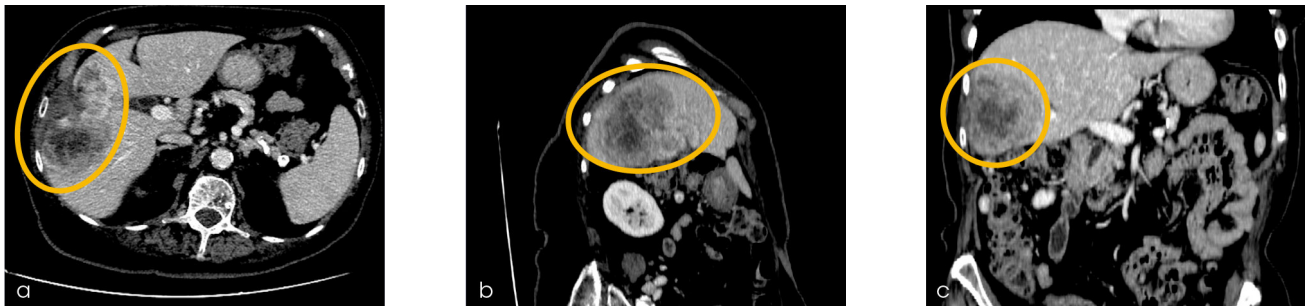

Figure 1: Abdominal follow-up CT before DSM-TACE showing disease progression

### DSM-TACE Procedure

- Procedure was performed in an angiographic suite, during patient monitoring and anesthesiological assistance under local anesthesia
- Anatomy of hepatic artery and possible branches to non-target structure was confirmed by common hepatic artery selective angiography, via transfemoral retrograde approach | Fig 2
- Super-selective lobar catheterization was performed using 1.9 Fr microcatheter
- Under fluoroscopic guidance, a solution of **450 mg in 7.5 ml** of microspheres type **EmboCept® S DSM 50  $\mu$ m** mixed with **50 mg Doxorubicin** and 21 ml non-ionic contrast medium was slowly infused in two steps:
  - Drug uptake: 50 mg of Doxorubicin diluted in 10 ml of saline solution plus 3.5 ml EmboCept® S DSM 50  $\mu$ m plus 15 ml non-ionic contrast medium was injected
  - 4 ml of EmboCept® S DSM 50  $\mu$ m plus 6 ml non-ionic contrast medium was injected to obtain stasis
- Endpoint for both steps was the delivery of the full planned dose with the achievement of an arterial stop-flow, which was achieved in all cases using EmboCept® S DSM 50  $\mu$ m

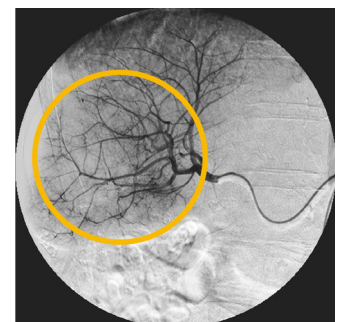


Figure 2: Hepatic artery selective angiography

## Outcome

- Partly transient elevation of hepatic enzymes (**AST** 90 U/l | **ALT** 19 U/l) and **serum bilirubin** (<2 mg/dl) at 1 day from procedure with return to normal values in three days without medical treatment
- Patient experienced mild nausea and abdominal pain, controlled and solved within 8 hours after procedure with standard medical therapy
- Patient was regularly dismissed after 48 hours, without any pain or periprocedural complications
- Partial response was apparent after second DSM-TACE (at 3-month follow-up) | Fig 3
- Tumor board decision was to **continue the treatment**
- **Complete response** with full necrosis of ICC with significant downsizing of residual liver parenchymal alteration after third DSM-TACE (at 6-month CT follow-up) | Fig 4 a-c

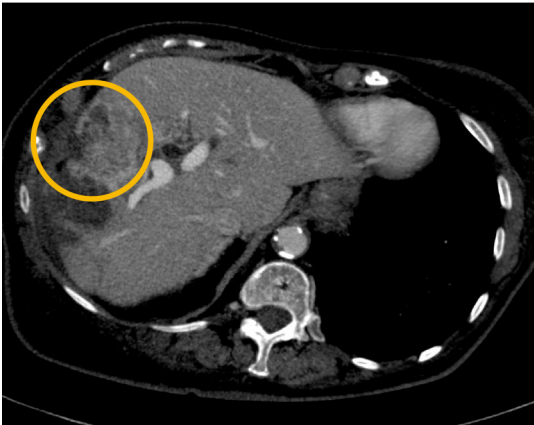


Figure 3: CT indicating partial response after second DSM-TACE at 3-month follow-up

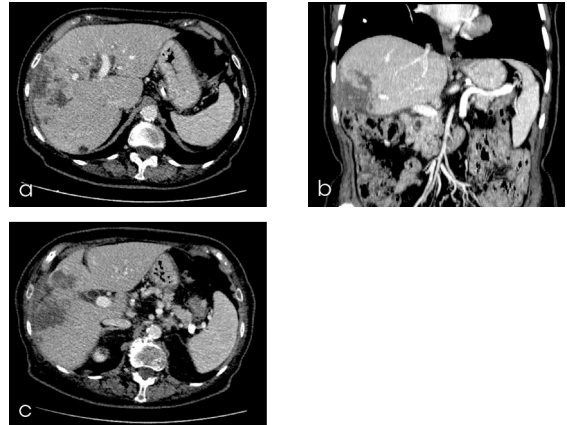


Figure 4: CT confirms complete response after third DSM-TACE at 6-month follow-up

## CONCLUSION

- EmboCept® S DSM 50 µm causes a temporary occlusion with a short ischemic period, allowing for an **optimal drug uptake**
- **Technical success** was achieved in all DSM-TACE procedures using EmboCept® S DSM 50 µm
- DSM-TACE allows repetitive treatment with an **optimal safety profile** and low drug related toxicities
- The use of EmboCept® S DSM 50 µm offers a very **effective treatment** option in ICC patients not being eligible for surgery or refractory to standard chemotherapy regimen

DSM Degradable Starch Microspheres  
ICC Intrahepatic cholangiocarcinoma  
TACE Transarterial chemoembolization



Magle PharmaCept GmbH, Cicerostrasse 2, 10709 Berlin, Germany  
Phone: +49-(0)30-7565985-0 · info@maglepharmaceut.com

EmboCept® is a registered trademark of Magle PharmaCept GmbH.  
© 2023 Magle PharmaCept GmbH, Berlin, Germany

20231105-01/2023